

## Spinal fusion on adolescent idiopathic scoliosis patients with the level of L4 or lower can increase lumbar disc degeneration with sagittal imbalance 35 years after surgery

Tsutomu Akazawa<sup>1)2)</sup>, Toshiaki Kotani<sup>2)</sup>, Tsuyoshi Sakuma<sup>2)</sup>, Shohei Minami<sup>2)</sup>, Sumihisa Orita<sup>3)</sup>, Kazuki Fujimoto<sup>3)</sup>, Yasuhiro Shiga<sup>3)</sup>, Masashi Takaso<sup>4)</sup>, Gen Inoue<sup>4)</sup>, Masayuki Miyagi<sup>4)</sup>, Yasuchika Aoki<sup>3)5)</sup>, Hisateru Niki<sup>1)</sup>, Yoshiaki Torii<sup>1)</sup>, Shigeta Morioka<sup>1)</sup>, Seiji Ohtori<sup>3)</sup> and Kazuhisa Takahashi<sup>3)</sup>

1) Department of Orthopaedic Surgery, St. Marianna University School of Medicine, Japan

2) Department of Orthopedic Surgery, Seirei Sakura Citizen Hospital, Japan

3) Department of Orthopedic Surgery, Graduate School of Medicine, Chiba University, Japan

4) Department of Orthopaedic Surgery, Kitasato University School of Medicine, Japan

5) Department of Orthopaedic Surgery, Eastern Chiba Medical Center, Japan

### Abstract:

**Introduction:** The purpose of this study was to investigate the long-term incidence of lumbar disc degeneration and Modic changes in the non-fused segments of patients with adolescent idiopathic scoliosis (AIS) who previously underwent spinal fusion.

**Methods:** Study subjects consisted of 252 patients with AIS who underwent spinal fusion between 1968 and 1988. Of 252 patients, 35 subjects underwent lumbar spine MRI and whole spine X-ray examination. The mean patient age at the time of follow-up was 49.8 years, with an average follow-up period of 35.1 years. We classified the subjects into two groups based on the lowest fused vertebra: H group whose lowest fused vertebra was L3 or higher levels and L group whose lowest fused vertebra was L4 or lower levels.

**Results:** The L group had significantly advanced disc degeneration on MRI. There was no significant difference between two groups in Modic changes. The L group showed less lumbar lordosis than the H group (H group: 48.1 degrees; and L group: 32.1 degrees) and greater SVA (H group: 1.2 cm; and L group: 5.5 cm).

**Conclusions:** In AIS patients, 35 years after spinal fusion surgery on average, we evaluated lumbar disc degeneration and Modic changes of the non-fused segments. In patients with the lowest fusion level at L4 or lower, there were reduced lumbar lordosis, considerable SVA imbalance, and severe disc degeneration compared with those with the lowest fusion level at L3 or higher. The lowest fusion level at L3 or higher is recommended to reduce disc degeneration in midlife.

### Keywords:

adolescent idiopathic scoliosis, spinal fusion, long-term follow-up, lumbar disc degeneration, Modic change

Spine Surg Relat Res 2017; 1(2): 72-77

dx.doi.org/10.22603/ssrr.1.2016-0017

### Introduction

Spinal fusion is often reported to have a good course for adolescent idiopathic scoliosis (AIS)<sup>1-5)</sup>. However, there are few reports on post-operative long-term changes at the adjacent levels of fusion when the patients reached their forties or fifties<sup>3)</sup>. There are concerns that those who underwent spinal fusion in adolescence may develop high incidence of lumbar disc degeneration associated with low back pain in

middle age.

Cochran et al. have reported that low back pain is more likely to occur in AIS patients in whom fusion was extended down to L4 or L5<sup>6)</sup>. Danielsson et al. examined MRIs of AIS patients fused to L4 or L5, and reported high incidence of disc degeneration associated with low back pain 25 years after surgery<sup>3)</sup>. Therefore, if the fusion levels are limited to L3 or higher preserving lower motion segments, we may expect less incidence of disc degeneration in the long-term pe-

riod.

On the other hand, Schwab et al. have reported positive correlations between pain and L3 or L4 vertebral body tilt in adult scoliosis<sup>7)</sup>. To prevent progression of adult scoliosis, which may cause pain, Toyone et al. recommended correcting L3 vertebral tilt to less than 5 degrees<sup>8)</sup>. In other words, L3 or L4 tilt should be corrected as much to get better outcomes in terms of low back pain in middle age.

For long-term prognosis, the incidence of low back pain is believed to be relatively low for those with spinal fusion down to L3 or higher. On the other hand, to correct L3 or L4 tilt sufficiently, it is advantageous to fuse down to lower levels. Therefore, there is a conflict for fusion levels: whether to preserve motion segments by limiting the fusion levels down to L3, or to secure correction of vertebral tilt by extending the fusion level down to L4 or lower.

The purpose of this study is to investigate the long-term incidence of lumbar disc degeneration and Modic changes of non-fused segments in AIS patients who underwent spinal fusion in their adolescence. Especially, we investigated whether the lowest level of fusion affected lumbar disc degeneration and whether such disc degeneration was related to low back pain and health-related quality of life (HRQOL). We hypothesized those AIS patients who were previously operated on with spinal fusion down to L4 or lower could develop low back pain in midlife due to advanced Modic changes associated with intervertebral disc degeneration of non-fused segments.

## Materials and Methods

The institutional review board approved the present study. Study subjects consisted of 252 patients with AIS who underwent spinal fusion at one institution between 1968 and 1988. All patients were younger than 20 years old at the time of surgery. The average age at the time of surgery was 14.8 years. The average Cobb angle was 68.3 degrees (range, 32-130 degrees) before surgery and 39.4 degrees (range, 6-90 degrees) two years after surgery. First, we tried to contact all the 252 patients by mail. The following patients were excluded: 134 patients with unknown address, 62 patients who failed to respond to the mails, 13 patients who refused examinations and 8 patients who died. Of 252 patients, 35 (30 women, 5 men) underwent lumbar MRI and whole spine X-ray examination. These 35 subjects were included in our analysis (follow-up rate of 13.9%). The mean age of the 35 subjects was 49.8 years (range, 40-64 years), with an average follow-up period of 35.1 years (range, 27-45 years). The surgical procedures used were posterior fixation in 30 patients and anterior fixation in 5. The lowest fusion levels were: T12 in 2; L1 in 4; L2 in 12; L3 in 9; L4 in 7; and L5 in 1. Preoperative X-ray or MRIs were not available in majority of the cases.

The MRI used was Signa HDxt 1.5 T (General Electric Company, Connecticut, USA). T1-weighted and T2-weighted sagittal images and cross-sections were obtained

for the lumbar spine. MRI evaluations were performed by three independent observers (O.S., F.K., and S.Y.) who were blinded to the clinical data of the patients. Pfirrmann classification was used to evaluate disc degeneration of the non-fused segments<sup>9)</sup>. This classification was performed by the three observers and the most voted values were selected as the gold standard. In the case that none of the observers coincide, the median value was selected. Modic changes were evaluated in terms of signal changes at the vertebral body endplate<sup>10,11)</sup>. Modic change evaluation was also performed by the three observers and the most voted types were selected as the gold standard. In the case that none of the observers coincide, the type was decided by discussion.

X-rays of the whole spine were taken from the back and the side with the subject standing. In the frontal view, we measured thoracic and lumbar Cobb angle, coronal balance (the difference between the line vertical from C7 and the sacral center line), and L3 and L4 vertebral tilt angles. The vertebral body tilt was measured as the angle formed by its superior endplate and a true horizontal line. In the lateral view, we measured thoracic kyphosis (TK: T5-T12), thoracolumbar kyphosis (TLK: T10-L2), lumbar lordosis (LL: L1-S1), pelvic incidence (PI), pelvic tilt (PT), and sagittal vertical axis (SVA: the distance between the line vertical from C7 and the S1 posterior corner). The questionnaires used were the Scoliosis Research Society Patient Questionnaire (SRS-22), Roland-Morris Disability Questionnaire (RDQ), and Oswestry Disability Index (ODI).

For statistical analyses, SPSS Statistics version 22.0 (International Business Machines Corporation, NY, USA) was used. We classified the subjects into two groups based on the lowest fused vertebra: H group whose lowest fused vertebra was L3 or higher levels; and L group L4 or lower levels. Pfirrmann grades 4 or 5 were considered lumbar disc degeneration positive (DD(+)), while those with other scores were considered negative (DD(-)). Those with Modic changes were named Modic(+), and those without Modic(-). For comparisons between two groups, we used the Mann-Whitney U test or chi-square test. The level of significance was set at less than 5%.

## Results

Patient data are shown in Table 1. There were Pfirrmann grade 1 in 1 segment, grade 2 in 28, grade 3 in 51, grade 4 in 32, and grade 5 in 8. Twenty-four patients (68.6%) had disc degeneration of Pfirrmann grade 4 or higher. Modic changes were found in 20 patients (57.1%): 15 had Modic change in one segment; 2 had Modic changes in 2 segments; 3 had Modic changes in 3 segments. There were Modic type 1 changes in 10 segments, Modic type 2 in 11, and Modic type 3 in 7. There was a case of central spinal stenosis on MRI, a case of foraminal stenosis at L5-S1, and a case of L5 spondylolytic spondylolisthesis, however, there was no disc herniation noted. Average SRS-22 scores were function: 4.3; pain: 4.5; self-image: 3.0; mental: 4.1; and

**Table 1.** Patient Data of the Study Group.

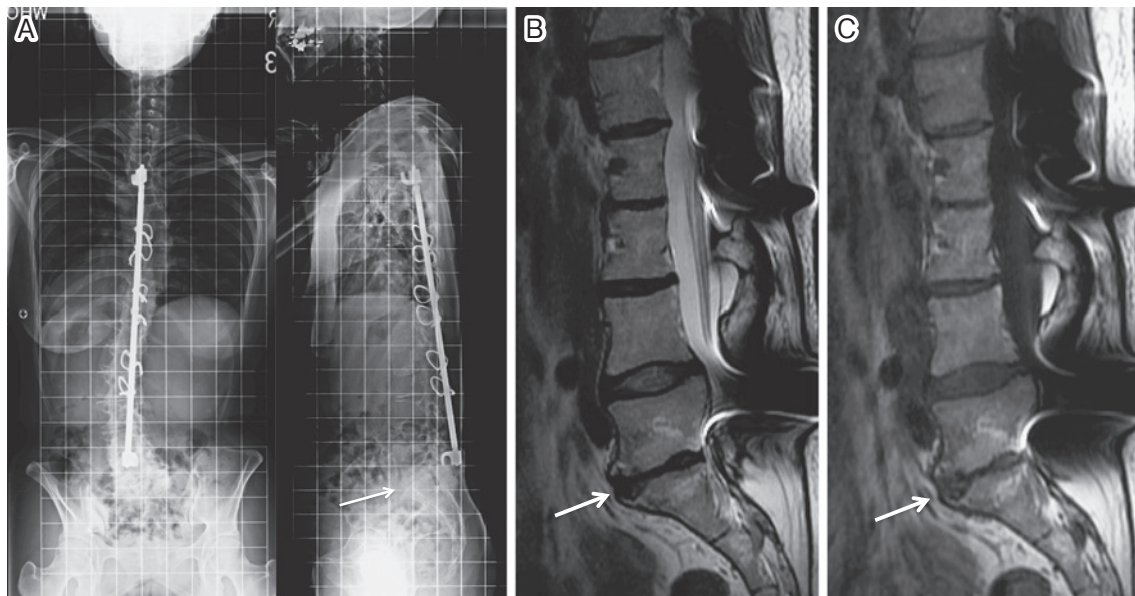
Case	Group	Sex	Demographics			X-ray parameters in coronal plane					X-ray parameters in sagittal plane					MRI					
			Age at the follow-up period (years)	Follow-up period (years)	BMI (kg/cm <sup>2</sup> )	Curve type	Surgical method	LFV	Thoracic curve (°)	Lumbar curve (°)	Coronal balance (cm)	L3 tilt (°)	L4 tilt (°)	TK (°)	TLK (°)	LL (°)	PI (°)	PT (°)	SVA (cm)	DD+/-	Modic+/-
1	H	F	55	41	18.3	D	HI	T12	67	51	0.9	2	14	55	9	53	35	15	-2.7	+	+
2	H	F	48	37	29.3	T	HI	T12	44	19	1.3	5	3	4	0	39	37	7	0.0	-	-
3	H	F	58	43	21.8	T	HI	L1	51	40	4.6	9	12	32	49	9	28	19	2.7	+	+
4	H	F	54	38	20.8	T	HI	L1	62	30	0.1	27	17	22	6	41	53	28	3.3	+	+
5	H	F	47	32	23.3	T	HI wiring	L1	40	30	1.1	2	5	26	18	35	43	29	-2.7	+	+
6	H	F	42	27	19.7	T	HI wiring	L1	42	15	2.8	4	0	35	2	52	31	5	0.0	-	-
7	H	F	56	43	23.1	T	HI	L2	84	52	1.8	20	6	37	8	47	63	23	9.4	+	+
8	H	F	60	44	20.6	T	HI	L2	65	52	3.3	6	12	27	11	45	44	13	4.8	+	+
9	H	M	54	39	14.0	T	HI	L2	69	24	4.2	27	24	45	27	61	38	4	0.0	-	-
10	H	F	49	37	20.0	T	HI	L2	53	18	1.2	17	17	33	16	53	47	20	4.8	+	+
11	H	F	51	34	34.8	T	HI	L2	51	18	3.7	12	9	33	4	35	87	50	16.8	+	-
12	H	M	47	32	20.8	T	HI wiring	L2	44	13	1.2	14	10	27	0	61	44	5	1.3	-	-
13	H	F	45	30	27.4	T	HI wiring	L2	60	29	0.8	16	9	46	7	55	35	8	0.0	-	-
14	H	F	43	29	17.9	T	HI wiring	L2	31	21	0.4	1	1	9	1	42	46	14	-0.6	-	-
15	H	F	47	28	18.4	T	HI wiring	L2	28	13	1.1	6	5	31	9	51	47	17	2.6	-	-
16	H	M	64	45	23.0	T	HI	L2	55	22	0.5	8	6	26	7	42	44	15	2.7	+	+
17	H	F	48	34	19.9	T	Luque	L2	26	19	0.4	0	6	18	10	42	41	15	0.2	+	-
18	H	F	45	32	19.5	T	HI wiring	L2	28	14	0.9	1	1	10	2	71	53	5	-4.7	-	-
19	H	F	54	42	17.3	T	HI	L3	71	21	2.5	25	29	24	13	32	45	27	3.4	-	-
20	H	F	51	39	19.4	T	HI	L3	74	38	0.6	8	6	61	20	66	42	10	0.2	-	-
21	H	F	45	31	20.6	D	Luque	L3	55	33	3.3	2	4	21	-2	75	47	4	-5.5	-	-
22	H	F	43	31	25.1	T	HI wiring	L3	38	19	0.7	8	2	33	7	68	69	29	1.2	+	+
23	H	F	40	29	18.0	T	HI wiring	L3	40	16	0.0	8	4	20	-5	62	36	3	-4.3	-	-
24	H	F	45	33	21.0	L	Zielke	L3	17	25	1.5	3	14	16	15	28	45	22	1.8	+	+
25	H	M	59	39	21.3	T	HI	L3	63	19	1.0	23	18	62	15	42	24	6	-0.6	+	+
26	H	F	55	37	19.0	T	HI	L3	33	19	1.2	4	2	37	11	53	40	12	-1.9	+	+
27	H	F	45	31	19.3	L	Zielke	L3	46	16	1.4	13	8	12	9	38	44	17	-1.0	+	+
28	L	F	52	37	22.7	D	HI	L4	33	33	1.6	5	9	28	12	42	48	19	5.4	+	+
29	L	F	51	37	20.5	L	Dwyer	L4	41	18	0.6	2	0	32	17	31	63	47	5.0	+	-
30	L	F	52	38	19.8	L	Dwyer	L4	41	20	4.3	0	3	19	20	28	38	14	6.4	+	+
31	L	F	49	30	19.0	L	Zielke	L4	41	33	0.6	0	4	21	6	37	34	9	1.3	+	+
32	L	F	43	27	21.7	D	Multi hook	L4	65	47	0.6	7	5	35	23	34	38	14	6.0	+	-
33	L	F	56	42	20.0	D	HI	L4	56	42	2.3	6	8	53	30	43	46	24	3.4	+	+
34	L	M	44	28	22.0	D	Multi hook	L4	42	28	4.3	4	10	14	11	14	44	21	8.4	+	+
35	L	F	46	32	22.3	D	HI wiring	L5	31	40	1.1	4	4	2	6	28	67	31	8.1	+	+

BMI: body mass index, LFV: the lowest fused vertebra, TK: thoracic kyphosis, TLK: thoracolumbar kyphosis, LL: lumbar lordosis, PI: pelvic incidence, PT: pelvic tilt, SVA: sagittal vertical axis, DD: disc degeneration with Pfirrmann grade 4 or 5, T: thoracic curve, D: double major curve, L: thoracolumbar/lumbar curve, HI: Harrington instrumentation.

satisfaction: 3.6. The average RDQ was 0.9, and the average ODI was 7.3.

There were 27 subjects classified into H group and 8 classified into L group. There were no significant differ-

ences between these two groups in terms of age at the time of follow-up (H group: 50.0 years, L group: 49.2 years, p=0.749), observation period following surgery (H group: 35.4 years, L group: 33.9 years, p=0.562), body mass index (H



**Figure 1.** A 46-year-old female. She underwent posterior spinal fusion with Harrington rods and wires at the age of 14 years. (A) X-rays taken 32 years after spinal fusion down to L5. Lateral radiograph showed flat back and sagittal imbalance with remained L5-S1 disc narrowing. (B) T2-weighted image of MRI. Non-fused L5-S1 disc was severely degenerated and the Pfirrmann disc score was graded 5. (C) T1-weighted image of MRI showed Modic type 2 change.

**Table 2.** MRI Findings of Lumbar Spine Degeneration: Comparison between H Group and L Group.

	H group	L group	P value
DD (+)	59.3%	100%	0.029*
Modic (+)	51.9%	75.0%	0.245

Pfirrmann grades 4 or 5 were considered lumbar disc degeneration positive (DD(+)), while those with other scores were considered negative (DD(-)). Those with Modic changes were named Modic(+), and those without Modic(-). \* indicates significant difference between groups.

**Table 3.** X-ray Parameters of H Group and L Group.

	H group	L group	P value
Thoracic curve (°)	49.5±16.8	43.8±11.4	0.536
Lumbar curve (°)	25.4±11.8	32.6±10.3	0.196
Coronal balance (cm)	1.6±1.3	1.9±1.6	0.831
L3 tilt (°)	10.0±8.4	3.5±2.6	0.033*
L4 tilt (°)	9.0±7.2	6.4±4.0	0.454
TK (T5-T12) (°)	29.7±14.9	25.5±15.3	0.712
TLK (T10-L2) (°)	10.8±10.6	15.6±8.5	0.216
LL (L1-S1) (°)	48.1±14.6	32.1±10.3	0.023*
PI (°)	44.7±12.7	47.2±11.9	0.724
PT (°)	15.6±10.7	22.3±12.0	0.332
SVA (cm)	1.2±4.5	5.5±2.3	0.007*

Values are mean (±: standard division). \* indicates significant difference between groups. TK: thoracic kyphosis, TLK: thoracolumbar kyphosis, LL: lumbar lordosis, PI: pelvic incidence, PT: pelvic tilt, SVA: sagittal vertical axis.

group: 21.2, L group: 21.0,  $p=0.711$ ), Cobb angle before surgery (H group: 73.5 degrees, L group: 57.3 degrees,  $p=0.191$ ), or Cobb angle two years following surgery (H group: 41.8 degrees, L group: 30.2 degrees,  $p=0.091$ ). Regarding curve type, among the subjects in the H group there were 23 patients with thoracic curve, 2 with thoracolumbar/lumbar curve, and 2 with double major curve. Among the subjects in the L group, there were 3 patients with thoracolumbar/lumbar curve and 5 with double major curve. As for the surgical procedure, for the H group, there were 14 cases of Harrington instrumentation, 9 of Harrington instrumentation with wiring, 2 of Luque wiring, and 2 of the Zielke method. For the L group, there were 2 cases of Harrington instrumentation, 1 of Harrington instrumentation with wiring, 2 of multiple hook, 2 of the Dwyer method, and 1 case of the Zielke method.

Sixteen of 27 patients in the H group had DD(+) (59.3%), compared with 8 of 8 in the L group (100%). The L group

had significantly advanced disc degeneration on MRI ( $p=0.029$ ) (Fig. 1). Fourteen of 27 patients in the H group had Modic changes (51.9%), compared with 6 of 8 in the L group (75.0%). There was no significant difference between the two groups in terms of Modic changes ( $p=0.245$ ) (Table 2).

There were no significant differences between the two groups in thoracic curve, lumbar curve, or coronal balance. L4 vertebral tilt was not significantly different between the two groups. However, the H group had greater L3 vertebral tilt than the L group. The L group showed less lumbar lordosis than the H group (H group: 48.1 degrees, L group: 32.1 degrees,  $p=0.023$ ) and greater SVA (H group: 1.2 cm,



**Table 4.** Questionnaire Scores of H Group and L Group.

	H group	L group	P value
SRS-22			
Function	4.3±0.6	4.4±0.3	0.511
Pain	4.5±0.5	4.3±0.7	0.371
Self image	3.0±0.8	2.9±0.7	0.696
Mental health	4.2±0.8	4.0±0.6	0.337
Satisfaction	3.7±0.7	3.3±0.9	0.167
RDQ	0.5±1.2	2.3±5.2	0.131
ODI (%)	6.8±8.4	8.9±8.3	0.661

Values are mean (±: standard deviation). RDQ: Roland-Morris Disability Questionnaire, ODI: Oswestry Disability Index.

L group: 5.5 cm,  $p=0.007$ ), in addition to sagittal plane imbalance (Table 3).

There were no significant differences between the groups in all domains of the SRS-22, the RDQ, or the ODI (Table 4).

#### *Intra-observer reliability of MRI evaluations*

Intra-observer reliability was calculated using intra-class correlation coefficients (ICC). ICC of Pfirrmann classification was 0.775, indicating good agreement, and ICC of Modic change was 0.800, indicating excellent agreement.

#### *Comparison between participants and non-participants*

Participants and non-participants were compared. There were no significant differences between these groups in terms of their age at surgery (participants:  $14.7\pm 2.0$  years vs. non-participants:  $14.8\pm 2.0$  years,  $p=0.580$ ), preoperative scoliosis curve ( $68.7\pm 21.0$  degrees vs.  $68.2\pm 20.0$  degrees,  $p=0.968$ ), and postoperative scoliosis curve 2 years after surgery ( $36.9\pm 15.3$  degrees vs.  $39.7\pm 16.3$  degrees,  $p=0.469$ ). When the percentages of participants and non-participants were compared by sex, there was no significant difference between these groups in terms of the percentage of women (participants: 85.7% vs. non-participants: 91.7%,  $p=0.253$ ).

## Discussion

Compared with those in the H group, subjects in the L group who underwent spinal fusion down to L4 or lower, disc degeneration progressed, lumbar lordosis was decreased, and sagittal imbalance was developed. Whether disc degeneration led to less lumbar lordosis and sagittal plane imbalance or whether disc generation was present from the time of surgery reducing lumbar lordosis was not verified, since there were no X-ray films remaining from the time before surgery or of progress since surgery. Hansen et al. reported that reductions in lumbar lordosis were due to increases in age-related disc degeneration<sup>12</sup>. Harding et al. pointed out that sagittal imbalance and/or malalignment of the spine following fusion were factors that contribute to ad-

jacent segment degeneration<sup>13</sup>. In the L group, because less motion segments were preserved, progress of age-related disc degeneration may lead to decreased lumbar lordosis.

In terms of most of the parameters for back pain and HRQOL score, the L group was generally inferior to H group, but no score reached statistical significance. Although SRS-22 pain, RDQ, and ODI score were worse in the L group, there were no statistically significant differences. It may be due to the small sample size of the L group of 8 patients. Since the present study was considerably long-term follow-up period, it was extremely difficult for us to include all the patients. In the future, we hope to attempt again to contact the patients who did not reply or refused doctor's visits.

There are several existing reports on non-fused intervertebral disc degeneration in patients who underwent spinal fusion for AIS. Green et al. compared AIS patients' preoperative MRIs with those from an average of 11 postoperative years later. They recognized progression of disc degeneration in 85% of the subjects, but it showed no association with low back pain<sup>14</sup>. Nohara et al. examined MRIs from AIS patients with an average of 12.8 years post hybrid method operation. They found that 48% of the patients had Pfirrmann grade 3 or higher intervertebral disc degeneration, but there was also no low back pain observed in their series<sup>15</sup>. On the other hand, Danielsson et al. with an average of 25 years following Harrington rod placement reported a relationship between the intensity of back pain and disc degeneration, in comparison to healthy controls<sup>3</sup>. In the present study, an average of 35 years after surgery, 68.6% of the patients had intervertebral disc degeneration of Pfirrmann grade 4 or higher. However, a previous study reported that MRI findings might not always be related to patient reported questionnaires<sup>16</sup>. Based on SRS-22, RDQ, and/or ODI, the findings did not relate to low back pain.

As far we know, there was no previous report on Modic changes between non-fused segments in AIS patients who underwent spinal fusion. In the current study, we detected Modic changes in 57.1% of the subjects. There are controversial reports about the relationship of low back pain and Modic changes. Toyone et al. reported MRI signal changes in vertebral endplates associated with back pain<sup>17</sup>. In a longitudinal cohort study, Määttä et al. characterized Modic changes as a risk factor for severe back pain<sup>18</sup>. Additionally, in an immunohistochemical study, Ohtori et al. detected the presence of tumor necrosis factor in a vertebral body endplate with Modic changes and reported this as a cause of low back pain<sup>19</sup>. On the other hand, Kovacs et al. reported no association of chronic low back pain with Modic changes<sup>20</sup>. In the present study, the presence of Modic changes was not associated with low back pain.

There are several limitations to our study. As our study had a very long follow-up period, there was a low follow-up rate. Half of our patients have relocated. In Japan, there is no national patient registry, so these patients could not be followed up. Additionally, in 25.8% of patients, there was

unfortunately no reply to our attempts at contact. This study had a considerably long follow-up period, and this time it was not possible to include any more patients. In the future, we are considering contacting again the patients who did not reply and those who declined to participate. Since X-ray films from the time of the original operations have been discarded, it was not possible to verify the preoperative condition of patients for comparison purposes. According to previous decision making of fusion level, the lowest fused vertebra was almost 2 levels below the lower end vertebra. But it was not possible to confirm the selection of the fusion level because of loss of the original films. In the present day, because imaging data are stored digitally rather than as physical films, data are easier to store and fears of losing them are reduced; for long-term follow-up studies, it will be necessary for a new generation of researchers to take over.

AIS patients with an average of 35 years after spinal fusion surgery showed lumbar disc degeneration in the non-fused intervertebral discs as well as Modic changes, though we could not observe related back pain or HRQOL changes. In patients with the lowest fusion level at L4 or lower, although L3 vertebral tilt in the coronal plane was small, there was reduced lumbar lordosis in the sagittal plane and considerable SVA imbalance, and disc degeneration had significantly progressed. There was no significant difference in RDQ or ODI related to low back pain. Although fusion levels depend on the curve types in most cases, the lowest fusion level at L3 or higher is recommended in order to reduce the risk of disc degeneration in midlife.

**Acknowledgments:** The authors thank Mr. Hideo Ishikawa, Mr. Mitoshi Ishino, Ms. Mika Fujiwara, and Ms. Mayumi Ishii for assistance on data collection.

**Conflicts of Interest:** The authors declare that there are no conflicts of interest.

## References

1. Akazawa T, Minami S, Kotani T, Nemoto T, Koshi T, Takahashi K. Long-term clinical outcomes of surgery for adolescent idiopathic scoliosis 21 to 41 years later. *Spine* 2012; 37(5): 402-405.
2. Bartie BJ, Lonstein JE, Winter RB. Long-term follow-up of adolescent idiopathic scoliosis patients who had Harrington instrumentation and fusion to the lower lumbar vertebrae: Is low back pain a problem? *Spine* 2009; 34(24): E873-E878.
3. Danielsson AJ, Cederlund CG, Ekholm S, Nachemson AL. The prevalence of disc aging and back pain after fusion extending into the lower lumbar spine: a matched MR study twenty-five years after surgery for adolescent idiopathic scoliosis. *Acta Radiol* 2001; 42(2): 187-197.
4. Danielsson AJ, Nachemson AL. Back pain and function 23 years after fusion for adolescent idiopathic scoliosis: a case-control study—part II. *Spine* 2003; 28(18): E373-E383.
5. Mariconda M, Galasso O, Barca P, Milano C. Minimum 20-year follow-up results of Harrington rod fusion for idiopathic scoliosis. *Eur Spine J* 2005; 14(9): 854-861.
6. Cochran T, Irstam L, Nachemson A. Long-term anatomic and functional changes in patients with adolescent idiopathic scoliosis treated by Harrington rod fusion. *Spine* 1983; 8(6): 576-584.
7. Schwab FJ, Smith VA, Biserni M, Gamez L, Farcy JP, Pagala M. Adult scoliosis: a quantitative radiographic analysis. *Spine* 2002; 27(4): 387-392.
8. Toyone T, Ozawa T, Inada K, Orita S, Ohtori S, Takahashi K. Horizontal fixation the L3 vertebra with a tilt of less than 5° can prevent the long-term curve progression of unfused adult scoliosis: ten-year follow-up study of concave PLIF at the wedged disc below the caudal end vertebra. *Spine* 2015; 40(5): 312-315.
9. Pfirrmann CW, Metzdorf A, Zanetti M, Hodler J, Boos N. Magnetic resonance classification of lumbar intervertebral disc degeneration. *Spine* 2001; 26(17): 1873-1878.
10. Modic MT, Steinberg PM, Ross JS, Masaryk TJ, Carter JR. Degenerative disk disease: assessment of changes in vertebral body marrow with MR imaging. *Radiology* 1988; 166: 193-199.
11. Zhang YH, Zhao CQ, Jiang LS, Chen XD, Dai LY. Modic changes: a systematic review of the literature. *Eur Spine J* 2008; 17(10): 1289-1299.
12. Hansen BB, Bendix T, Grindsted J, et al. Effect of lumbar disc degeneration and low-back pain on the lumbar lordosis in supine and standing: a cross-sectional MRI study. *Spine* 2015; 40(21): 1690-1696.
13. Harding IJ, Charosky S, Vialle R, Chopin DH. Lumbar disc degeneration below a long arthrodesis (performed for scoliosis in adults) to L4 or L5. *Eur Spine J* 2008; 17(2): 250-254.
14. Green DW, Lawhorne TW 3rd, Widmann RF, et al. Long-term magnetic resonance imaging follow-up demonstrates minimal transitional level lumbar disc degeneration after posterior spine fusion for adolescent idiopathic scoliosis. *Spine* 2011; 36(23): 1948-1954.
15. Nohara A, Kawakami N, Seki K, et al. The effects of spinal fusion on lumbar disc degeneration in patients with adolescent idiopathic scoliosis: a minimum 10-year follow-Up. *Spine Deform* 2015; 3: 462-468.
16. Kelly DM, McCarthy RE, McCullough FL, Kelly HR. Long-term outcomes of anterior spinal fusion with instrumentation for thoracolumbar and lumbar curves in adolescent idiopathic scoliosis. *Spine* 2010; 35(2): 194-198.
17. Toyone T, Takahashi K, Kitahara H, Yamagata M, Murakami M, Moriya H. Vertebral bone-marrow changes in degenerative lumbar disc disease. *J Bone Joint Surg [Br]* 1994; 76-B(5): 757-764.
18. Määttä JH, Wadge S, MacGregor A, Karppinen J, Williams FMK. Vertebral endplate (Modic) change is an independent risk factor for episodes of severe and disabling low back pain. *Spine* 2015; 40(15): 1187-1193.
19. Ohtori S, Inoue G, Ito T, Koshi T, Ozawa T. Tumor necrosis factor-immunoreactive cells and PGP 9.5-immunoreactive nerve fibers in vertebral endplates of patients with discogenic low back pain and Modic type 1 or type 2 changes on MRI. *Spine* 2006; 31(9): 1026-1031.
20. Kovacs FM, Arana E, Royuela A, et al. Vertebral endplate changes are not associated with chronic low back pain among Southern European subjects: a case control study. *AJNR Am J Neuroradiol* 2012; 33(8): 1519-1524.

Spine Surgery and Related Research is an Open Access article distributed under the Creative Commons Attribution - NonCommercial - NoDerivatives 4.0 International License. To view the details of this license, please visit (<https://creativecommons.org/licenses/by-nc-nd/4.0/>).