

Radical surgery consisting of en bloc corpectomy in recurrence after palliative surgery for spinal metastasis

Shurei Sugita¹⁾, Hideki Murakami¹⁾, Noritaka Yonezawa¹⁾, Satoru Demura¹⁾, Sakae Tanaka²⁾ and Hiroyuki Tsuchiya¹⁾

1) Department of Orthopaedic Surgery, Kanazawa University, Japan

2) Department of Orthopaedic Surgery, Faculty of Medicine, The University of Tokyo, Japan

Abstract:

Introduction: We often experience recurrence of spinal metastases after palliative surgery, even with radiotherapy. We examined the clinical outcome of radical surgery containing en bloc corpectomy for patients with recurrent spinal metastasis.

Methods: Seven patients underwent en bloc corpectomy for recurrent spinal metastases. We assessed the prognosis scores (Tomita, Tokuhashi), pre- and postoperative Frankel scale scores, operation time, intraoperative blood loss, and perioperative complications.

Results: The preoperative estimated prognosis was less than six months (two patients), six months to one year (two patients), and over one year (three patients), according to Tokuhashi score. Major perioperative complications were dura mater injury and pleural injury. Neurological improvement was seen in four patients. All patients were ambulatory at discharge and lived longer than the preoperatively estimated life expectancy (range: seven months to four years).

Conclusions: Radical surgery consisting of en bloc corpectomy may be a therapeutic choice for patients with recurrent spinal metastases.

Keywords:

spinal metastasis, recurrent tumor, surgery, en bloc corpectomy

Spine Surg Relat Res 2017; 1(2): 96-99

dx.doi.org/10.22603/ssrr.1.2016-0020

Introduction

Spinal metastasis is a clinically challenging condition, with a morbidity rate of approximately 30% among cancer patients. In addition, 5% of cancer patients develop neurological deterioration during the clinical course¹⁾. The clinical burden of these conditions is substantial due to the increasing life expectancy accompanying recent advances in oncological therapies.

The purposes of treatment for spinal metastasis are to prevent tumor recurrence, to decompress the spinal cord to avoid spinal paralysis, and to restore the alignment and stability of the spine²⁾. To achieve these purposes, surgical decompression and stabilization of the spine combined with radiotherapy is often used. This method has been proven to be an effective treatment³⁾, but patients sometimes experience tumor recurrence, at rates of 32%-69%^{4,5)}. Surgically dealing with such recurrences is quite difficult because of preceding radiation, scar tissue formation, and conglutina-

tion of the dura mater.

Under these conditions, if the patients' general status is good and they can tolerate operation, we treat the recurrent spinal metastases by radical surgery containing en bloc corpectomy. We adapted the technique of total en bloc spondylectomy, as we previously reported⁶⁾. We herein report the clinical outcomes of radical surgery containing en bloc corpectomy for recurrent spinal metastasis.

Materials and Methods

Patients

Between January 2011 and December 2014, 81 patients underwent surgery for spinal metastasis in our hospital. We retrospectively reviewed the records of 7 patients out of 81 patients (5 male, 2 female; median age: 59 years old, range: 45-65 years; Table 1) who underwent en bloc corpectomy for recurrent spinal metastases. Every patient underwent

Corresponding author: Shurei Sugita, ssugita-ky@umin.ac.jp

Received: November 13, 2016, Accepted: December 12, 2016

Copyright © 2017 The Japanese Society for Spine Surgery and Related Research

posterior decompression with or without posterior fixation for the first surgery. We retrospectively collected the data regarding the prognosis scores (Tomita⁷, Tokuhashi⁸ score), pre- and postoperative Frankel scale scores, operation time, intraoperative blood loss, and perioperative complications from the medical record.

Surgical procedure

Each patient underwent preoperative embolization of segmental arteries, including one level above and one level below the tumor site. Decompression of the spinal cord was accomplished by piece-by-piece tumor and scar resection. En bloc corpectomy was performed using a routine surgical procedure⁶. The anterior column was reconstructed by a vertebral spacer packed with autograft bone. During each surgery, the range of posterior fixation was two levels above and two levels below the tumor site.

Statistical analysis

Statistical analyses were performed using the JMP[®] version 11 software program (SAS, Cary, NC, USA). Descriptive statistics were used to analyze the clinical information,

demographic factors, and other test data. The continuous variables were expressed as the medians and interquartile range (IQR) or means and standard deviation (SD). The differences in the motor scores after treatment were examined using Student's *t*-test. A *P* value <0.05 was considered to be statistically significant.

Results

The preoperative statuses of all patients are shown in Table 2. All patients but one were ambulatory. The preoperative estimated prognosis was less than six months (two patients), between six months and one year (two patients), and over one year (three patients), according to Tokuhashi score.

The factors related to surgical treatment are shown in Table 3. Due to preoperative artery embolization, the intraoperative bleeding amount was acceptable (median: 520 g) except for in one patient (6,240 g). The major perioperative complications were dura mater injury (in five) and partial pleural injury (in four). Dural injuries were treated by suture, polyglycolic acid sheet, and fibrin glue. Pleural injuries were treated by suturing. No cerebrospinal fluid leakage occurred after surgery, and no pneumothorax or hemothorax requiring additional treatment occurred.

Neurological improvement was seen in four patients. All of the patients were ambulatory at discharge. Local recurrence of the tumor was observed in four patients. All of the patients lived longer than preoperatively estimated (range: seven months to four years; Table 4). Four patients were still alive at the end of the study.

Illustrative case

A 63-year-old female who had a history of thyroid cancer

Table 1. Demographic Data of Patients Included in This Study.

	Age	Sex	Tumor
Case 1	64	Male	Gastrointestinal stromal tumor
Case 2	63	Female	Thyroid cancer
Case 3	53	Male	Lung cancer
Case 4	45	Male	Chondrosarcoma
Case 5	59	Female	Breast cancer
Case 6	56	Male	Renal cell cancer
Case 7	65	Male	Renal cell cancer

Table 2. Preoperative Statuses of Patients Included in This Study.

	Affected level	1st surgery	Radiation therapy	Frankel scale scores	Tomita score	Tokuhashi score	Estimated prognosis (month)
Case 1	T5	Decompression	No	E	2	12	12<
Case 2	T4-6	Decompression and fixation	No	C	3	9	6-12
Case 3	T2-4	Decompression and fixation	Yes	E	10	6	<6
Case 4	T10	Decompression and fixation	No	E	2	12	12<
Case 5	T6-7	Decompression and fixation	Yes	D	2	12	12<
Case 6	T5-6	Decompression and fixation	Yes	D	4	8	6-12
Case 7	T11-L1	Fixation	Yes	D	8	6	<6

Table 3. The Factors Related to Surgical Treatment.

	excised vertebra	bleeding (g)	operation time (min)	dura mater injury	pleural injury
Case 1	T5	520	445	yes	yes
Case 2	T4-6	6240	628	yes	no
Case 3	T2-4	330	522	no	yes
Case 4	T10	640	455	no	no
Case 5	T6-7	450	506	yes	no
Case 6	T5-6	100	442	yes	yes
Case 7	T11-L1	605	503	yes	yes

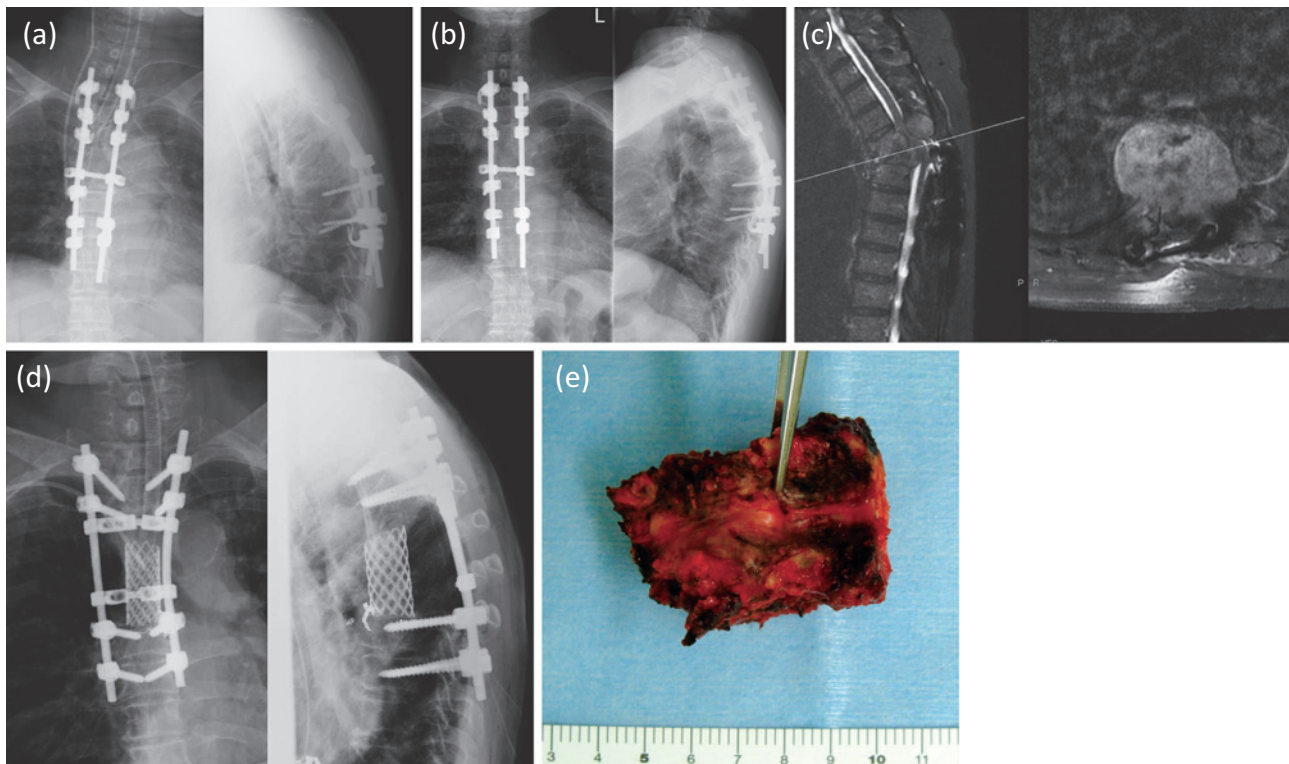


Figure 1. Plain radiographs (a) soon after the first surgery, (b) right before the second surgery. (c) MRI images of the recurrent tumor after the first surgery. (d) Plain radiographs after the second surgery. (e) Excised vertebra.

Table 4. Postoperative Outcomes of Patients.

	Frankel scale scores	life prognosis (month)	local tumor recurrence
Case 1	E	29	Yes (1 year)
Case 2	E	48<	No
Case 3	E	31	Yes (3 months)
Case 4	E	47<	No
Case 5	D	35<	No
Case 6	E	40<	Yes (2.5 months)
Case 7	E	7	Yes (1.5 months)

and thyroidectomy 20 years prior developed paraparesis due to spinal metastasis of the thoracic spine. She underwent posterior decompression and fixation (Fig. 1a, 1b). Two years later, the tumor had relapsed; enlargement of tumor led to paraparesis again, and she became non-ambulatory (Fig. 1c). She was referred to our hospital and underwent surgery. After piecemeal resection of the posterior element of spine, en bloc corpectomy of T4 to T6 was done (Fig. 1d, 1e). The tumor was hypervascular, and the intraoperative blood loss was substantial (6,240 g). The neurological findings recovered soon (Frankel C to Frankel E), and she was ambulatory at discharge. She is still alive at four years after the surgery with no sign of local recurrence.

Discussion

In our study, radical surgery consisting of en bloc corpectomy was performed without life-threatening complications,

and all of the patients lived longer than initially predicted before surgery. Most surgeons avoid surgical treatment of patients with metastatic spinal tumor whose estimated survival is very short. To determine the surgical indications, several scoring systems, such as the Tokuhashi score⁸⁾, Tomita score⁷⁾, and Katagiri⁹⁾ score, are often used. However, these scoring systems differ from reality because recent advances in oncological treatment (i.e., molecular-targeting drugs) have improved the prognosis of patients with spinal metastases.

All patients included in our study had undergone palliative surgery for spinal metastases once, and the metastases had relapsed. Given these circumstances, the prognosis of these patients was anticipated to be quite grim and the life expectancy very short. Indeed, four of the seven patients were estimated before operation to survive less than one year after surgery, according to those scoring systems. However, in reality, all of them survived beyond the estimated expectancy.

The origins of metastases in these patients were thyroid cancer, lung cancer, and renal cell carcinoma, all of which could be treated by multi-modality methods. For example, metastasectomy of renal cell carcinoma has been proven to improve the prognosis^{10,11)}. In addition, molecular-targeting drugs aimed at treating lung cancer, renal cell cancer, and colorectal cancer are newly emerging¹²⁾. These present data show that patients with spinal metastases can live longer than estimated using currently available scores and be treated with aggressive surgical metastasectomy. With these circumstances, the clinical outcome of TES surgery has

changed as we previously reported¹³⁻¹⁵. In our hospital, now we determine the indication of TES surgery or en bloc corpectomy case by case taking consideration of all factors: age, comorbidity, affected spinal level, and size of tumor, and type of cancer.

However, aggressive metastasectomy led to an increased incidence of complications, dura mater injury (5/7, 71%), and partial pleural injury (4/7, 57%). The general incidence of postoperative complications with spinal metastases is reported to be around 20%¹⁶. Our series showed even higher incidence, indicating the large invasiveness of this surgery. However, there were no life-threatening complications.

Several limitations associated with the present study warrant mention. First, the number of cases in this study was relatively small, so we cannot extrapolate the results of this study to larger populations in future studies. Second, all of the patients in our study were referred to our hospital for the purpose of undergoing surgery. We cannot exclude selection bias, as other patients in worse condition may have been eliminated before visiting our hospital.

Conclusion

Radical surgery consisting of en bloc corpectomy may, therefore, be a promising therapeutic strategy for patients with recurrent spinal metastases.

Conflicts of Interest: The authors declare that there are no conflicts of interest.

References

- Gomez JA. The incidence of vertebral body metastases. *Int Orthop* 1995; 19: 309-11.
- Black P. Spinal metastasis: current status and recommended guidelines for management. *Neurosurgery* 1979; 5: 726-46.
- Patchell RA, Tibbs PA, Regine WF, et al. Direct decompressive surgical resection in the treatment of spinal cord compression caused by metastatic cancer: a randomised trial. *Lancet* 2005; 366: 643-8. eng.
- Lau D, Leach MR, La Marca F, Park P. Independent predictors of survival and the impact of repeat surgery in patients undergoing surgical treatment of spinal metastasis. *J Neurosurg Spine* 2012; 17: 565-76.
- Laufer I, Hanover A, Lis E, Yamada Y, Bilsky M. Repeat decompression surgery for recurrent spinal metastases. *J Neurosurg Spine* 2010; 13: 109-15.
- Tomita K, Kawahara N, Baba H, Tsuchiya H, Nagata S, Toribatake Y. Total en bloc spondylectomy for solitary spinal metastases. *Int Orthop* 1994; 18: 291-8.
- Tomita K, Kawahara N, Kobayashi T, Yoshida A, Murakami H, Akamaru T. Surgical strategy for spinal metastases. *Spine*. 2001; 26: 298-306.
- Tokuhashi Y, Matsuzaki H, Toriyama S, Kawano H, Ohsaka S. Scoring system for the preoperative evaluation of metastatic spine tumor prognosis. *Spine*. 1990; 15: 1110-3.
- Katagiri H, Takahashi M, Wakai K, Sugiura H, Kataoka T, Nakanishi K. Prognostic factors and a scoring system for patients with skeletal metastasis. *Bone Joint J* 2005; 87: 698-703.
- Kato S, Murakami H, Demura S, et al. Spinal metastasectomy of renal cell carcinoma: a 16-year single center experience with a minimum 3-year follow-up. *J Surg Oncol* 2016; 113: 587-92.
- Ljungberg B. The role of metastasectomy in renal cell carcinoma in the era of targeted therapy. *Curr Urol Rep* 2013; 14: 19-25.
- Palazzo A, Iacovelli R, Cortesi E. Past, present and future of targeted therapy in solid tumors. *Curr Cancer Drug Targets* 2010; 10: 433-61.
- Sugita S, Murakami H, Demura S, et al. Repeated total en bloc spondylectomy for spinal metastases at different sites in one patient. *Eur Spine J* 2015; 24: 2196-200.
- Sugita S, Murakami H, Kato S, Tanaka S, Tsuchiya H. Disappearance of lung adenocarcinoma after total en bloc spondylectomy using frozen tumor-bearing vertebra for reconstruction. *Eur Spine J* 2016; 25: 53-7.
- Kimura H, Fujibayashi S, Shimizu T, et al. Successful total en bloc spondylectomy of T7 vertebra for hepatocellular carcinoma metastasis after living donor liver transplantation. *Spine*. 2015; 40: E944-7.
- Choi D, Fox Z, Albert T, et al. Rapid improvements in pain and quality of life are sustained after surgery for spinal metastases in a large prospective cohort. *Br J Neurosurg* 2016; 30: 337-44.

Spine Surgery and Related Research is an Open Access article distributed under the Creative Commons Attribution - NonCommercial - NoDerivatives 4.0 International License. To view the details of this license, please visit (<https://creativecommons.org/licenses/by-nc-nd/4.0/>).